

# Prevention of oral and salivary gland impairment in irradiated adolescent patients with head and neck cancer: A suggested protocol

Esti Davidovich, DMD, MSc<sup>1</sup>/Benjamin Peretz, DMD<sup>1</sup>/  
Doron J. Aframian, DMD, PhD<sup>2</sup>

Patients with head and neck cancer receive high doses of localized irradiation therapy, which results in destruction of salivary gland secretion ability. Pilocarpine hydrochloride was shown to have some beneficial effect on quality of life of these patients. Most studies concentrated on adult patients with head and neck cancer with no reference to adolescents. This case report demonstrates the long-term beneficial effect of pilocarpine hydrochloride in maintaining sufficient saliva, oral soft tissue integrity, and caries-free status in an adolescent cancer patient who received a total radiation dose of 6,000 cGy. A suggested protocol for management of irradiated adolescent patients with head and neck cancer is offered. (*Quintessence Int* 2007;38:235–239)

**Key words:** adolescent, head and neck radiation, pilocarpine hydrochloride, salivary function, salivary glands

About 8,000 cases of cancer are diagnosed annually in children in the United States, with a tendency to increase each year.<sup>1</sup> The 3 most common cancers diagnosed in children are leukemia, central nervous system tumors, and lymphoma, which account for about 70% of all new cancers seen in this age group.<sup>1</sup> Sarcomas account for less than 1% of all malignancies in the United States, with about 30% occurring in the head and neck region in childhood.<sup>1</sup> Fibrosarcoma has an intermediate 5-year survival of 60% to 70%.<sup>2</sup>

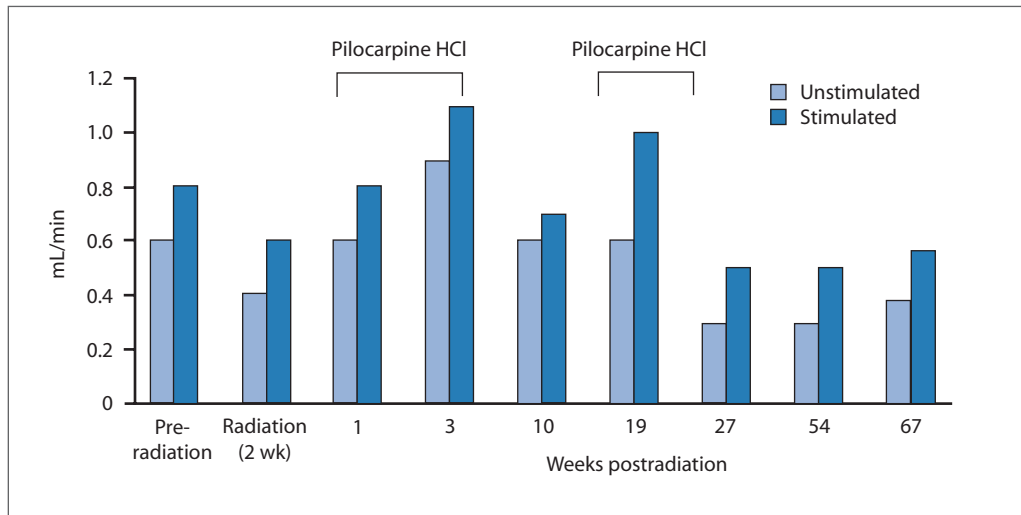
Management of most cancers in children requires multimodality treatments, including chemotherapy, localized or total-body radiation therapy, and surgery. Management of these patients becomes important since up to 90% of them may suffer an oral complication of some kind.<sup>3</sup> Chemotherapy has usually transient effects on oral health. However, radiotherapy induces direct and irreversible oral complications if irradiated fields include the maxillofacial areas, particularly the major salivary glands.<sup>4</sup> Furthermore, longer-term orofacial complications of radiotherapy to the head and neck region include dry mouth (xerostomia), loss of taste, limitation of jaw movements, and, less commonly, osteoradionecrosis.<sup>5</sup> Xerostomia is due to irreversible damage to the glandular epithelium manifested by extreme salivary hypofunction.

Saliva is integral to many functions, such as cleansing, lubrication, food-bolus formation, chewing, and swallowing. Taste perception and the promotion of oral soft tissue integrity and remineralization of hard tissues are further important functions of saliva.

<sup>1</sup>Department of Pediatric Dentistry, The Hebrew University-Hadassah School of Dental Medicine, Jerusalem, Israel.

<sup>2</sup>Salivary Gland Clinic, Department of Oral Medicine, The Hebrew University-Hadassah School of Dental Medicine, Jerusalem, Israel.

**Reprint requests:** Dr Doron J. Aframian, Salivary Gland Clinic, Department of Oral Medicine, The Hebrew University-Hadassah School of Dental Medicine, P.O.B. 12272, Jerusalem, Israel 91120. Fax: 972-2-644-7919. E-mail: daframian@yahoo.com



**Fig 1** Time course of unstimulated and stimulated whole salivary flow before, during, and after radiation therapy.

Saliva also contributes to the maintenance of the ecologic balance of oral microflora.<sup>6</sup> Patients with xerostomia, therefore, suffer from rampant dental caries, frequent mucosal infections, and difficulties in swallowing and chewing dry food. They also experience alterations in taste sensation and perception, as well as considerable pain originating from the salivary glands, coughing episodes, voice disturbances, speech difficulties, and discomfort, all of which significantly decrease their quality of life.<sup>7</sup>

In children, cancer therapy also results in long-term enamel hypoplasia, microdontia, delay or failure of tooth development and eruption, and altered root formation, as well as maldevelopment of the craniofacial skeleton.<sup>8</sup>

Several clinical trials have demonstrated the efficacy of pilocarpine as a systemic sialogogue in adults.<sup>9</sup> Salivary flow was shown to be significantly enhanced following pilocarpine treatment compared with placebo; furthermore, 5 months of pilocarpine therapy produced no serious adverse effects.<sup>9</sup>

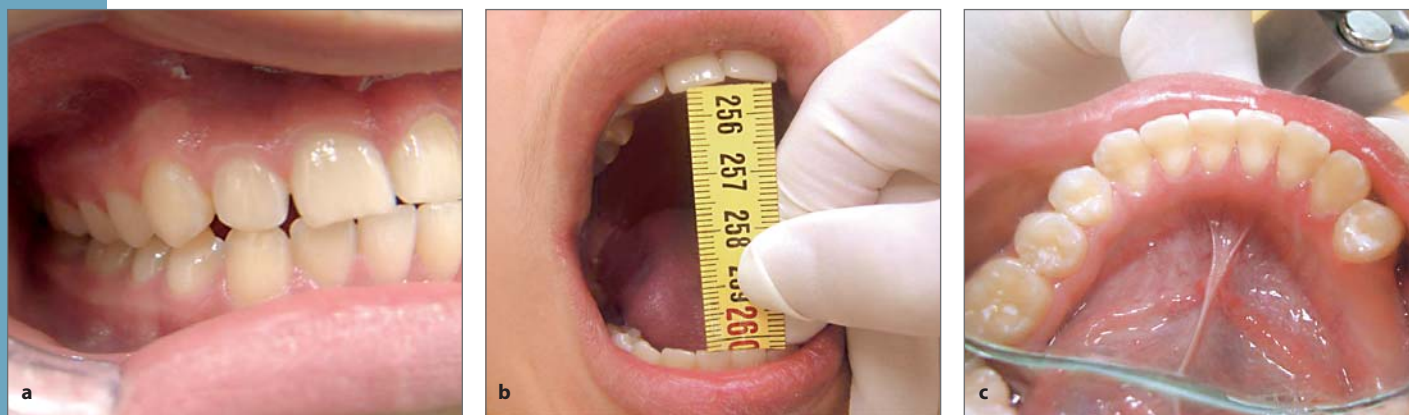In the present study, pilocarpine hydrochloride (HCl) was administered for the prevention and treatment of radiation-induced salivary gland impairment in a 12-year-old boy treated with radiotherapy after fibrous

sarcoma was disclosed on the left side of the mandible. Guidelines for dental treatment in oncologic-pediatric patients have been published.<sup>10</sup> However, to our knowledge only 1 case has been published in the English literature addressing administration of pilocarpine HCl in children and suggesting that this treatment may be effective.<sup>11</sup>

## CASE REPORT

A 12-year-old patient was referred to our maxillofacial surgery department with a large mass on the left side of his jaw. Biopsy revealed fibrous sarcoma. Following ablative surgery, the mandible was reconstructed with an autologous fibula bone graft. The boy was treated with supplemental fractional radiotherapy to the left side of the mandible, 200 cGy per session for 5 weeks (total of 6,000 cGy).

Oral examination before radiation therapy revealed only 2 caries foci with normal soft tissue appearance. The caries lesions were treated, and the child was given strict oral hygiene instructions including fluoridated mouthrinses.



**Figs 2a to 2c** Oral status 27 weeks after irradiation therapy. (a) No plaque, gingivitis, recession, or cervical caries is evident. (b) No trismus is evident; 48-mm opening is demonstrated. (c) No caries foci are evident, and a normal bath of saliva in the floor of the mouth is seen.

During the radiation therapy, application of fluoride varnish was performed during weekly follow-up visits to prevent development of rampant caries. Oral examination for infection and mucosal integrity was done as well. Pilocarpine HCl, 5 mg tid, was initiated immediately after completion of radiation therapy. Because of poor compliance, pilocarpine was stopped after 1 month of administration and was readministered again 3 months later (Fig 1).

Whole unstimulated salivary flow (WUSF) at rest and with 2% citric acid stimulation (WSF) was monitored before and during pilocarpine HCl therapy. Before irradiation therapy, WUSF and WSF were 0.6 and 0.8 mL/min respectively. After 2 weeks (2,200 cGy radiation dose), salivary flow decreased by about 30% and reached 0.4 mL/min for WUSF and 0.6 mL/min for WSF (Fig 1). Administration of pilocarpine HCl induced an increase in salivary flow; however, 10 weeks later, a decrease in salivary flow was observed. Readministration of pilocarpine for an additional 9 weeks induced a repeated increase in salivary flow rates. Steady salivary flow rates were evident 6, 12, and 15 months later (see Fig 1).

During radiation therapy the patient complained of a burning-mouth sensation, loss of taste, and dry mouth; however, all complaints

were diminished after radiation therapy ended and pilocarpine was administered. Fifteen months later, the patient was caries free, with no mucosal injuries or infections, no masticatory fibrosis, and no complaint of dry mouth (Fig 2).

## DISCUSSION

This case highlights several important points about treatment for irradiation-induced salivary gland impairment in adolescent patients. Extreme salivary hypofunction in these patients is a consequence of irreversible damage to the glandular epithelium from the therapeutic radiation regimen, usually those exceeding 5,000 cGy. Indeed, recent studies suggest that a mean dose of 2,600 cGy should be the planning goal if substantial sparing of salivary glands is desired.<sup>12</sup>

In the present study, pilocarpine HCl was administered for the treatment of radiation-induced dry-mouth symptoms in an adolescent with fibrous sarcoma of the mandible. Pilocarpine was administered in 2 phases: immediately after radiation therapy completion and 3 months later for an additional 9 weeks.

<b>Table 1 Irradiation adverse effects and proposed management in adolescent patients undergoing head and neck irradiation<sup>3,4,7-11,14-17</sup></b>		
	<b>Adverse effects</b>	<b>Suggested treatment protocol</b>
Pre-irradiation	Dental caries	Noncariogenic diet; removal of caries foci, plaque, primary mobile tooth with irritation potential; fluoride administration (varnish, trays, gels, dentifrices, rinses); removal of orthodontic appliances
	Gingival and periodontal health	Meticulous oral hygiene
	Masticatory system	Daily stretching exercises
	Salivary glands	Sialogogue administration (pilocarpine HCl), amifostine, 3D-IMRT, parotid-sparing IR, salivary gland transfer technique
During irradiation		Weekly follow-up
	Dental caries	Noncariogenic diet; removal of caries foci and plaque; fluoride administration (varnish, trays, gels, dentifrices, rinses)
	Gingival and periodontal health	Meticulous oral hygiene
	Masticatory system	Daily stretching exercises
	Salivary glands	Sialogogue administration (pilocarpine HCl), salivary stimulation with chewing gum, mint lozenges, artificial salivary replacement, amifostine, 3D-IMRT, parotid-sparing IR
	Dysgeusia and dysphagia	Copious fluids, nonacidic intake with eating
	Oral soft tissues	Tongue cleansing, lip moistening, lubricant gels
	Oral infections	Antifungal treatment (rinses, ointments, lozenges, tongue cleansing); antibiotics, chlorhexidine mouthwash; antiviral therapy
	Mucositis	Chlorhexidine mouthwash, topical anesthetics and systemic analgesics, cold oral non-acidic application, topical analgesic solutions
Postirradiation, immediately (0-3 mo)	Dental caries	Noncariogenic diet, removal of caries foci, fluoride administration (varnish, trays, gels, dentifrices, rinses)
	Gingival and periodontal health	Meticulous oral hygiene
	Masticatory system	Daily stretching exercises
	Salivary glands	Sialogogue administration (pilocarpine HCl), salivary stimulation with chewing gum, mint lozenges, artificial salivary replacement
Postirradiation, late (3 mo-1.5 y)	Dental caries	Monthly follow-up Noncariogenic diet, fluoride administration (varnish, trays, gels, dentifrices, rinses)
	Gingival and periodontal health	Meticulous oral hygiene
	Masticatory system	Daily stretching exercises
	Salivary glands	Sialogogue administration (pilocarpine HCl), salivary stimulation with chewing gum, mint lozenges, artificial salivary replacement

(3D-IMRT) 3-dimensional, intensity-modulated radiation therapy; (IR) irradiation therapy.

Upon pilocarpine administration, subjective as well as objective improvement in salivary secretion was demonstrated up to 15 months after radiation therapy completion.

Salivary flow measurements did not fall below 0.2 mL/min. (The "cutoff" value between normal and abnormal WUSF is 0.1 mL/min).<sup>13</sup>

The guidelines of the American Academy of Pediatric Dentistry for the management of pediatric dental patients receiving chemotherapy, hematopoietic cell transplantation, and/or radiation addressed briefly the treatment protocol of xerostomia in children and adolescents.<sup>10</sup> To our knowledge, only 1 case has been published in the English literature addressing administration of pilocarpine HCl in children and suggesting that this treatment can be effective.<sup>11</sup> Based on our experience, a revised protocol is proposed (Table 1).

## CONCLUSION

Adequate salivary secretion as well as integrity of hard and soft tissues in the oral cavity was achieved in an adolescent after irradiation to the head and neck region by using pilocarpine hydrochloride, meticulous oral hygiene treatment, and masticatory muscle exercise. Further large-scale research of this affected group of patients is needed to assess the beneficial use of pilocarpine hydrochloride.

## REFERENCES

1. Sturgis EM, Potter BO. Sarcomas of the head and neck region. *Curr Opin Oncol* 2003;15:239–252.
2. Wanebo HJ, Konecny RJ, MacFarlane JK, et al. Head and neck sarcoma: Report of the Head and Neck Sarcoma Registry. Society of Head and Neck Surgery Committee on Research. *Head Neck* 1992; 14:1–7.
3. Chin EA. A brief overview of the oral complications in pediatric oncology patients and suggested management strategies. *ASDC J Dent Child* 1998;65: 468–473.
4. Scully C, Epstein JB. Oral health care for the cancer patient. *Eur J Cancer B Oral Oncol* 1996;32B: 281–292.
5. Sonis ST, Fey EG. Oral complications of cancer therapy. *Oncol* 2002;16:680–686, 691–692, 695.
6. Soto-Rojas AE, Kraus A. The oral side of Sjögren syndrome. Diagnosis and treatment. A review. *Arch Med Res* 2002;33:95–106.
7. Ship JA. Diagnosing, managing, and preventing salivary gland disorders. *Oral Dis* 2002;8:77–89.
8. Fayle SA, Duggal MS, Williams SA. Oral problems and the dentist's role in the management of paediatric oncology patients. *Dent Update* 1992;19: 152–156, 158–159.
9. Valdez IH, Wolff A, Atkinson JC, Macynski AA, Fox PC. Use of pilocarpine during head and neck radiation therapy to reduce xerostomia and salivary dysfunction. *Cancer* 1993;71:1848–1851.
10. American Academy of Pediatric Dentistry. Guidelines for the Management of Pediatric Dental Patients Receiving Chemotherapy, Hematopoietic Cell Transplantation, and/or Radiation [Reference Manual]. Available at: [http://www.aapd.org/media/Policies\\_Guidelines/G\\_Chemo.pdf](http://www.aapd.org/media/Policies_Guidelines/G_Chemo.pdf). Accessed 26 Nov 2006.
11. Deutsch M. The use of pilocarpine hydrochloride to prevent xerostomia in a child treated with high dose radiotherapy for nasopharynx carcinoma. *Oral Oncol* 1998;34:381–382.
12. Eisbruch A, Ten Haken RK, Kim HM, Marsh LH, Ship JA. Dose, volume, and function relationships in parotid salivary glands following conformal and intensity-modulated irradiation of head and neck cancer. *Int J Radiat Oncol Biol Phys* 1999;45:577–587.
13. Sreebny LM, Valdini A. Xerostomia. Part I: Relationship to other oral symptoms and salivary gland hypofunction. *Oral Surg Oral Med Oral Pathol* 1988;66:451–458.
14. Kennedy L, Diamond J. Assessment and management of chemotherapy-induced mucositis in children. *J Pediatr Oncol Nurs* 1997;14:164–174.
15. da Fonseca MA. Dental care of the pediatric cancer patient. *Pediatr Dent* 2004;26:53–57.
16. Vissink A, Burlage FR, Spijkervet FK, Jansma J, Coppes RP. Prevention and treatment of the consequences of head and neck radiotherapy. *Crit Rev Oral Biol Med* 2003;14:213–225.
17. Chambers MS, Garden AS, Kies MS, Martin JW. Radiation-induced xerostomia in patients with head and neck cancer: Pathogenesis, impact on quality of life, and management. *Head Neck* 2004;26:796–807.